

# Novel Treatment of an Enteroatmospheric Fistula with Transforming Powder Dressing

Ron Sotomayor, RN, BA, CWOCN; A Non-profit Hospital In Florida

Southeast Region of the Wound, Ostomy and Continence Nurse Society 2023 Conference | Winston-Salem, NC | August 24 – 26

## BACKGROUND

Despite advances in surgical care, enteroatmospheric fistulas (EAFs) present a highly challenging and devastating problem in wound care therapy.<sup>1</sup> Proper management of EAFs is critical to improving recovery and fistula healing and requires rapid intervention to prevent sepsis.<sup>2</sup> EAF standard of care (SOC) is variable and may include dressings, pouches, floating stoma, and negative pressure wound therapy (NPWT).<sup>3</sup>

Proper wound care management is vital to ensure wound healing and prevent sepsis. Therefore, alternative treatments to address the following criteria must be considered:

- Promote wound healing
- Isolate the fistula to permit proper treatment
- Improve patient quality of life (QoL)
- Reduce overall healthcare costs

## CASE OVERVIEW

A 37 y/o female presented with extensive trauma to the chest and abdomen following a motor vehicle accident (Day 1). Treatment included wound vac placement on the patient's abdomen. Computed tomography revealed a colo-cutaneous fistula extending from the right colon into the right pelvic wall. Post-operative procedures involved the right colon, left lower quadrant colostomy and an ileal loop extending into the right pelvic wall, likely representing ileostomy. Hospital course was complicated by a high output EAF extending from the right colon into the right pelvic wall, a left sided abdominal wound measuring 13cm x 11cm x 3.5cm, and three stomatized abdominal fistulae on the right. As the wound was refractory to SOC treatment, NPWT treatment was discontinued (Day 11). Treatment was switched to an expensive specialty pouch (\$900-\$1,200/each). Due to high output effluent, the pouch required two drainage bags, suction set up and two replacements per week with two staff members dedicating two-hours per replacement.

The patient was discharged home with instructions to return to the Ostomy Clinic for appliance replacement 1-2 times per week. She was subsequently readmitted to the hospital with a fever and indications of sepsis.

## METHODOLOGY & MATERIALS

Upon readmission, and because the wound was refractory to SOC treatment, wound treatment was converted to a Transforming Powder Dressing (TPD\*), a novel dressing with which our team had successful experiences in complex wounds.

TPD is comprised primarily of biocompatible polymers. Upon hydration with saline, TPD granules aggregate to form a moist, oxygen-permeable matrix that protects the wound from contamination while helping to manage excess exudate through vapor transpiration. Once applied, TPD may be left in place for up to 30 days and more powder may be added as needed without requiring full dressing changes. Simple secondary dressings were used in areas of high exudation or friction. The TPD remained adhered in the wound bed promoting proliferation and flaked off as the wound healed

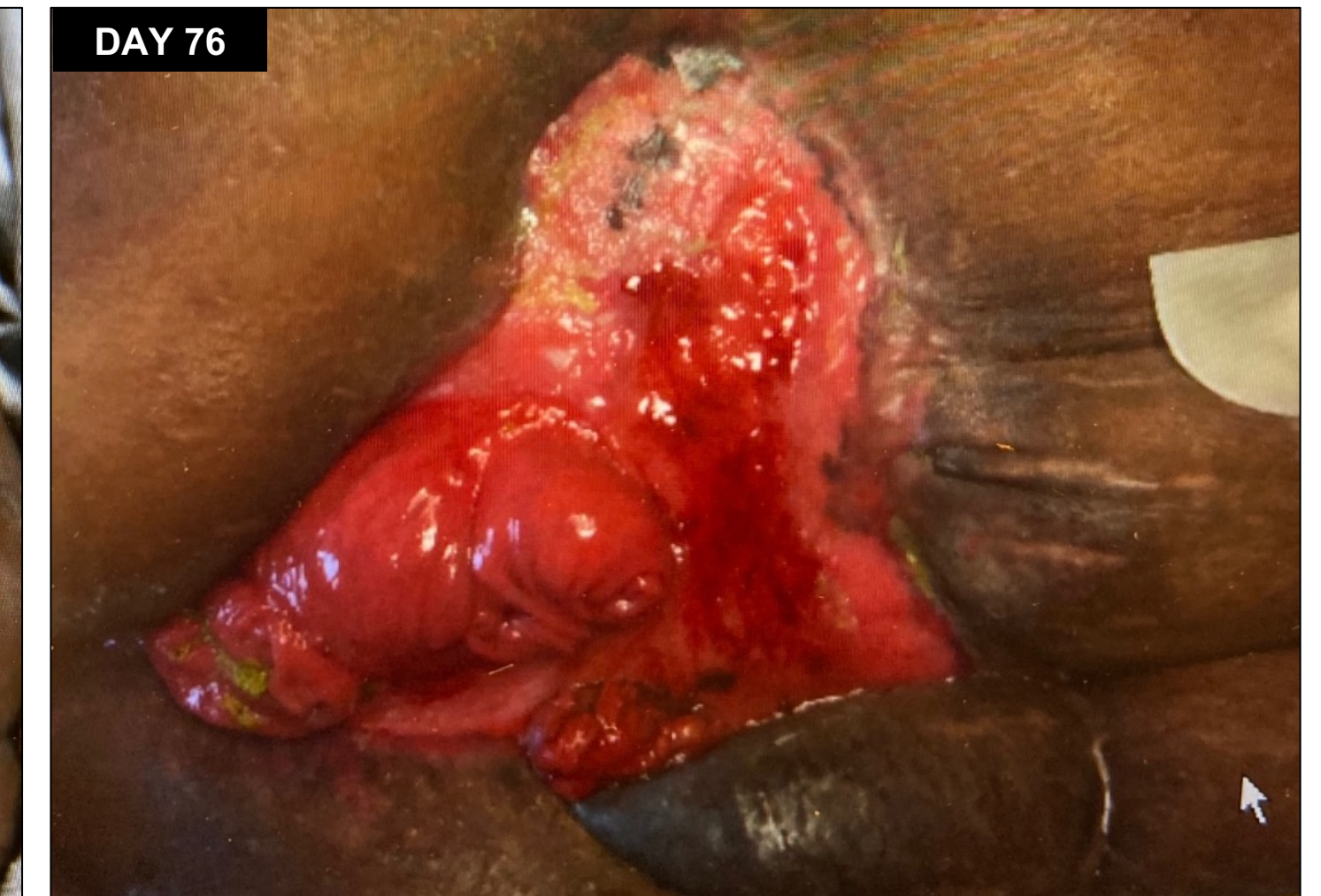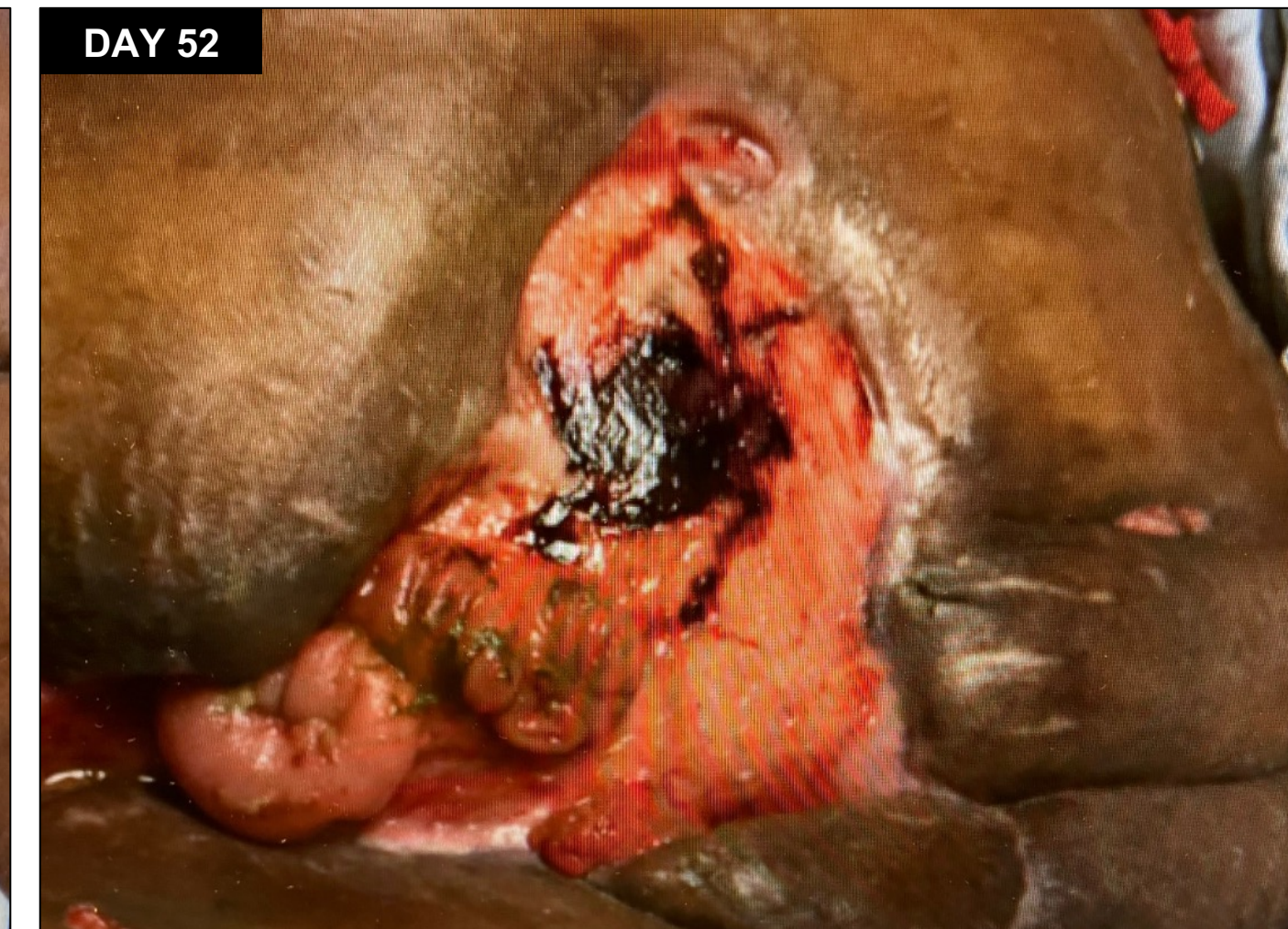
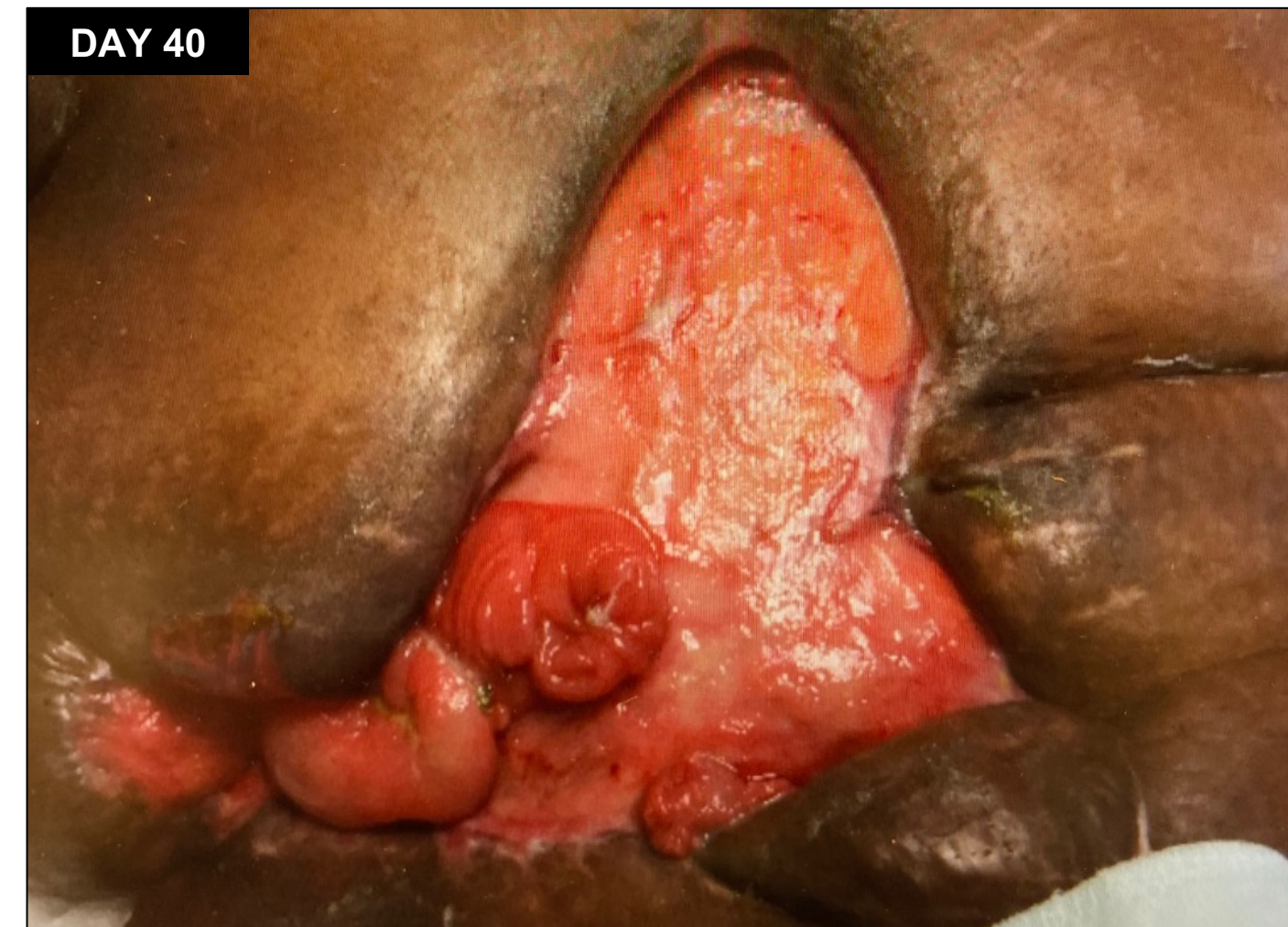
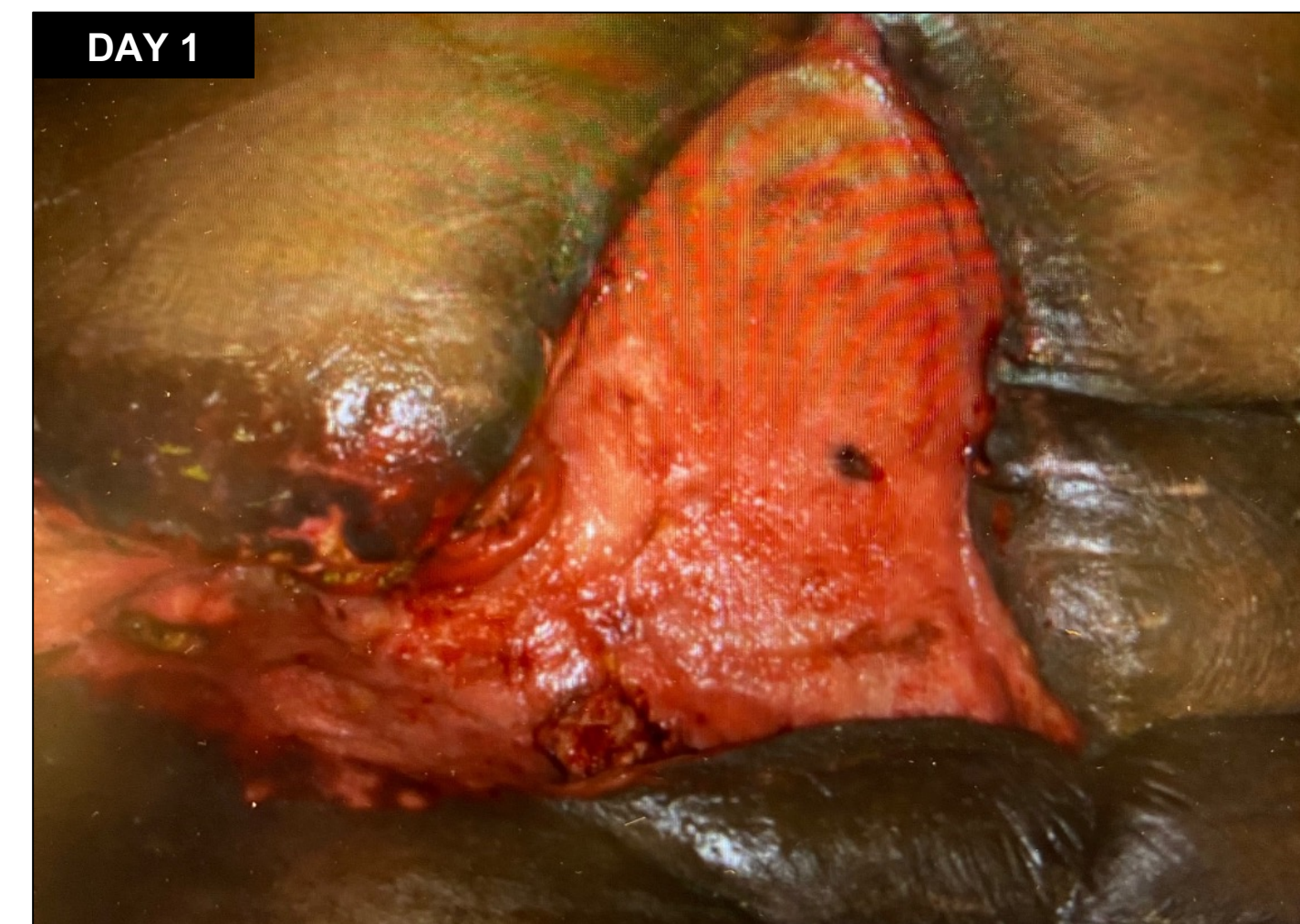
The patient was discharged home and returned to the clinic three weeks later. The wound had decreased in size (9cm x 8cm x 1.2cm), and the stomatized fistulae were able to be isolated with a smaller, less costly patient management appliance. Within 10-days of initial TPD treatment, the patient was able to resume daily living activities.

\*Altrazeal® Transforming Powder Dressing (USA)

## RESULTS

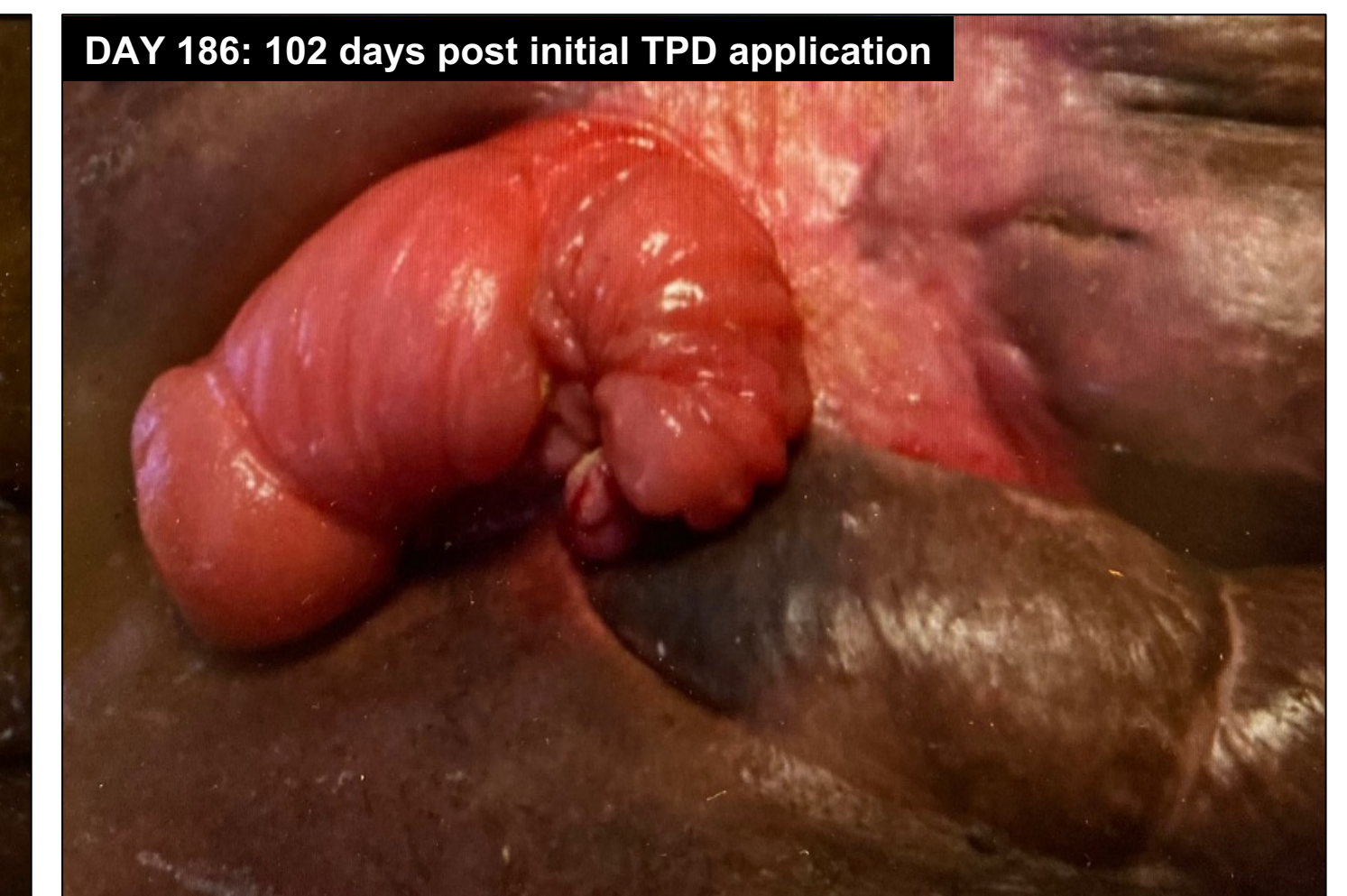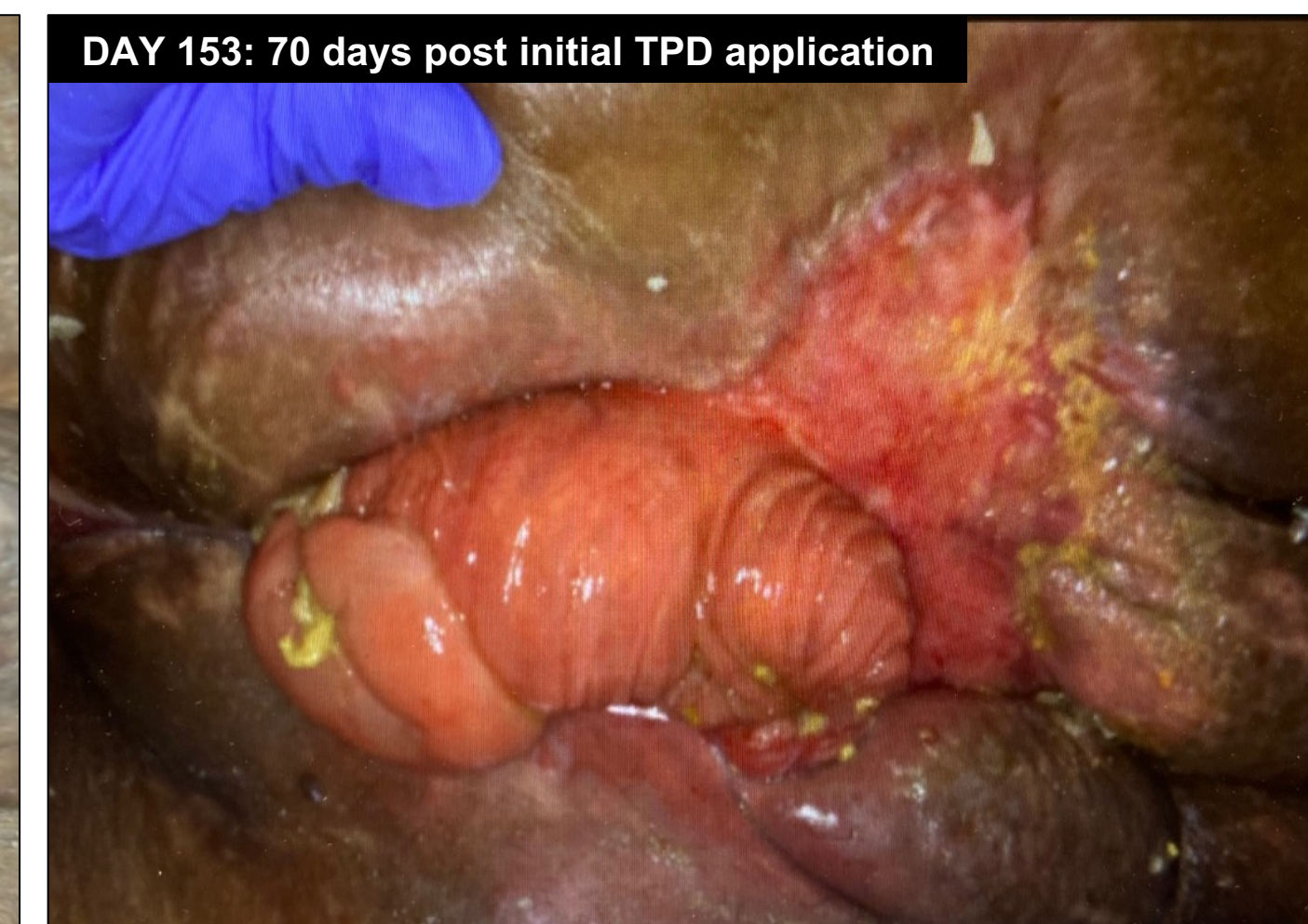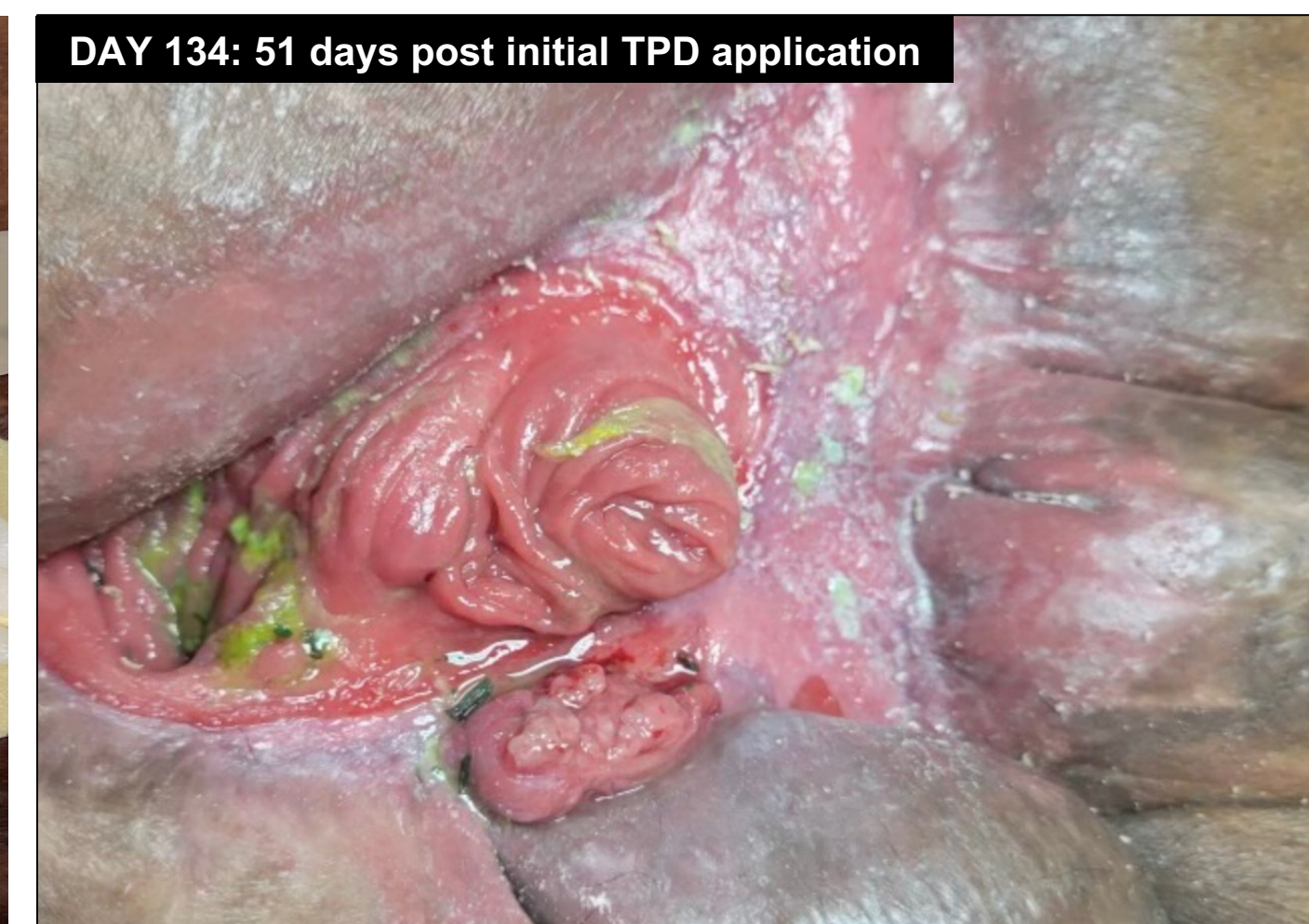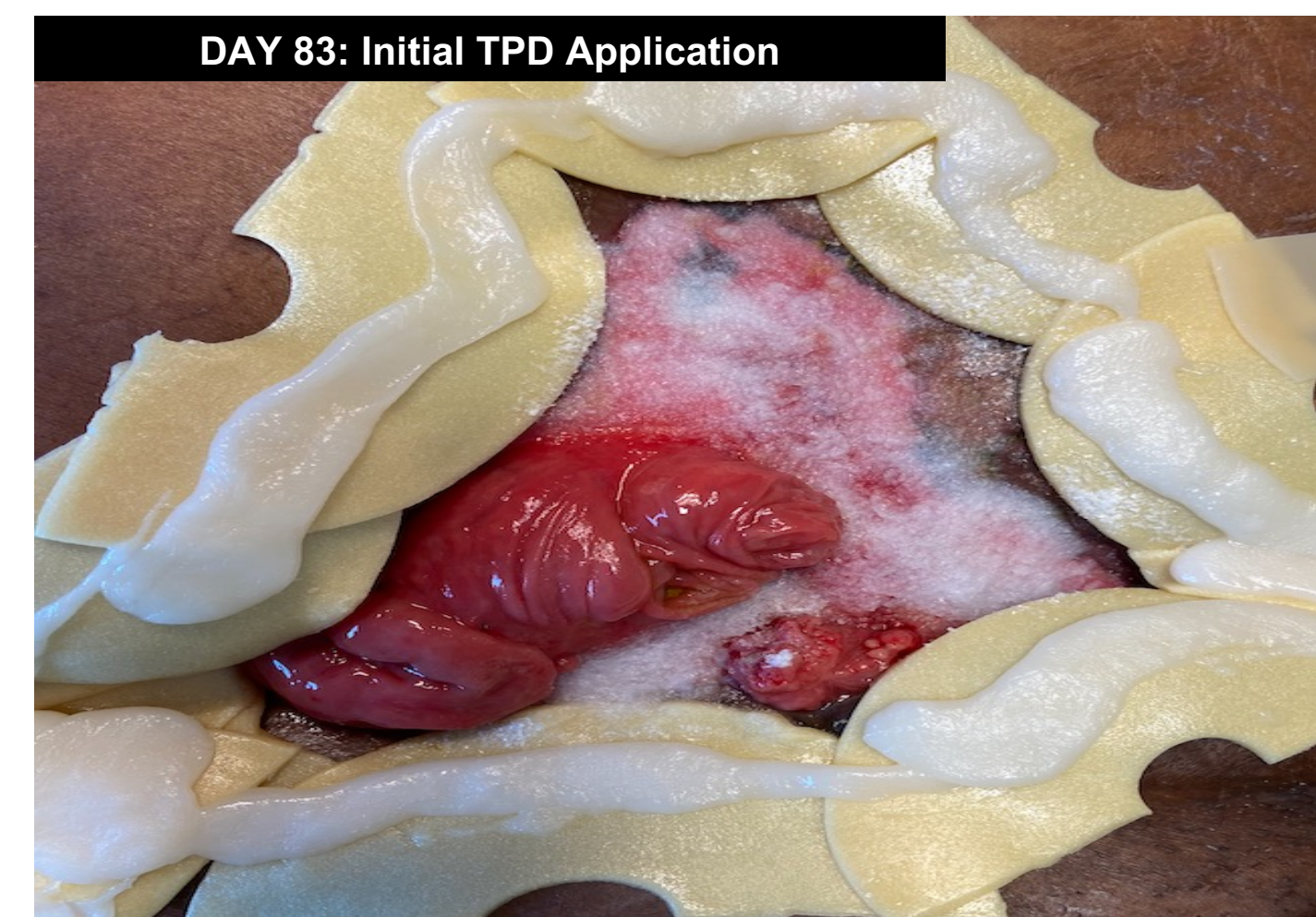### SOC Treatment Course for first 11 weeks (prior to TPD application):

- Wound measurement on admission: 13cm x 11cm x 3.5cm
- NPWT: Utilized post-admission to day 11
- Specialty Pouches: Due to high output effluent, 2 drainage bags, suction set up, replacement twice/week, and 2 staff members for 2 hours were required for each change
- Wound was refractory to SOC treatment



### Treatment Course Post TPD Application:

- Wound significantly decreased in size after 3 weeks of TPD treatment: 9cm x 8cm x 1.2cm
- Fistulae were isolated with less costly appliance
- Frequency of dressing changes reduced compared to SOC
- Total labor resource allocation requirements reduced compared to SOC
- Patient resumed activities of daily living within 10 days of initial TPD treatment



## CONCLUSION

In this case study, conversion of wound treatment from SOC to TPD resulted in:

- Facilitation of wound healing
- Isolation of the fistula
- Formation of a barrier protecting the excoriated skin from fluids and thus promoting proliferation
- Improved QoL
- Reduction of labor resources and supply costs

Based on the clinical observations and outcomes of this case study, the use of TPD provided a safe and effective modality for the treatment of this challenging wound and EAF.

## REFERENCES AND ACKNOWLEDGEMENTS

- (1) Meshikhes AW, Al-Hariri A, Al-Zahir AA, Al-Nahawi M. A rare approach to entero-atmospheric fistula. Am J Case Rep. 2013;14:476-480. Published 2013 Nov 13. doi:10.12659/AJCR.889638.
- (2) Ludlow E. What is an Entero-cutaneous Fistula and Entero-atmospheric Fistula? <https://www.insidescompany.com/blog/what-is-an-enterocutaneous-fistula-and-enteroatmospheric-fistula/>; Published online 2020 Nov 9.
- (3) Terzi C, Egeli T, Canda AE, Arslan NC. Management of enteroatmospheric fistulae. Int Wound J. 2014;11 Suppl 1(Suppl 1):17-21. doi:10.1111/iwj.12288

**Acknowledgements:** This poster was presented in collaboration with Altrazeal Life Sciences Inc. All protocols and clinical assessments were conducted independently without any compensation.